

ROOT WORDS

Promoting just a little bit of knowledge...and a whole lot of Healthy Smiles

Mission Statement

To provide excellent endodontic care in a professional, friendly environment by a highly trained and motivated team!

We work to fulfill our mission by making patient care our #1 goal.

WILLIAM L. BEASLEY, D.D.S.
LESLIE B. HARDY, JR., D.D.S.
DAYNA S. DUKE, D.D.S.
MYRON S. HILTON, D.D.S.

4500 W. MEMORIAL CIRCLE
OKLAHOMA CITY, OK 73142

8101 SOUTH WALKER
OKLAHOMA CITY, OK 73139

(405) 748-6000
1-800-522-9609
FAX (405) 749-5900

www.eaokc.com

Sodium Hypochlorite and Endodontics

One of the main purposes of a root canal is to eliminate tissue, bacteria and toxins from the root canal system. Instrumentation alone is not enough to totally clean the canals. Therefore, irrigating solutions are used to complete the cleaning process. These solutions help flush out debris and act as a lubricant during instrumentation.

The most commonly used solution is sodium hypochlorite (NaOCL). It has physicochemical and antibacterial properties that make it perfect for debridement and sterilization, and it is inexpensive and readily available. It is used in concentrations ranging from .5% to 5.25% with a variety of temperatures. The higher the concentration and temperature, the more effective the solution is in dissolving tissue.

We use 5.25% (concentration out of the bottle) and we heat it using a hot plate. Always use a side delivery irrigating needle and never lock or wedge it in the canal. Inject slowly and watch for flow-back of the solution.

The ability of NaOCL to dissolve organic tissue is very powerful. Not only will it dissolve pulpal tissue, it will destroy periapical tissue if it comes in contact with it. This will cause acute inflammation followed by necrosis.

If the solution is injected into the surrounding tissue, there will be immediate pain, bleeding from the canal and edema in the surrounding area. The swelling can be rapid and significant

and there could be enough damage that permanent paresthesia occurs.

Accident management:

1. Recognize the problem and inform the patient (they will already know there is a problem!)
2. Immediately irrigate the canal with saline solution to dilute the NaOCL.
3. Allow the canal to bleed to help flush out the solution.
4. Apply an ice pack to help control swelling for two to four hours.
5. Leave the tooth open and have the patient use saline rinses until they return in one week to have the tooth closed.
6. Prescribe pain medications. The area will be painful for several days.
7. Reassure the patient, because they will be scared to death.

Sodium hypochlorite is an excellent irrigating solution when used properly. ■

Dr. Lee Beasley earned both his D.D.S. degree and masters degree in endodontics at the University of Iowa. A native of Oklahoma City, Dr. Beasley has served as past president of the Oklahoma Dental Association, the Oklahoma County Dental Association and the Oklahoma Association of Endodontists. He is also active in the American Dental Association and the American Association of Endodontists.



Quality Patient Care in a Comfortable Environment


Introducing
Melissa Etheridge...

Melissa joined our team this past July after graduating from dental assisting school in June.

Staff Vitals

Melissa Etheridge

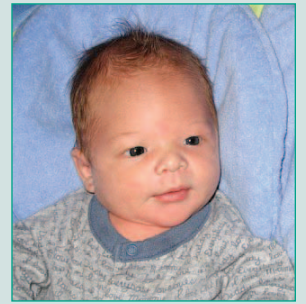Newly wed to her high school sweetheart in 2006, Melissa and her husband Scott enjoy watching OU football, going to concerts and playing with their dog Phoebe. She also "loves" to shop and is an avid reader.



Melissa Etheridge
Endodontic Assistant

Bravo

■ **Casey Petrillo** (EA business assistant) and her husband Derek are the proud parents of Andrew Ronald. Their son was born Nov. 30th and weighed 8 pounds 7 ounces, measuring 21 inches long.



Melissa is a great addition to the EA family! She says that she loves being a dental assistant because it's a way for her to meet new and interesting people, and it allows her to help patients. Working with such a wonderful staff in a high-tech environment makes coming to work very rewarding.

We hope
you and your
families
all enjoyed the
holidays!



From
Dr. Beasley,
Duke, Hardy
and Hilton,
our best
wishes for
2008.



Gina Cannon, Adrienne Steenberg and Susan Renee' Newman join Dr. Beasley in a photo.



Franki Stout and Cortney Harmon are all smiles at EA's Christmas party.



Carla Howell, Mandi McConnell and Reba Creech all dressed in their holiday finery!

Please share this fun and helpful information with your staff by passing on *ROOT WORDS!* If you would like additional copies of this newsletter, please call Gina at Endodontic Associates, (405) 748-6000 or (800) 522-9609.